

Long-Term Outcomes of Patients Receiving a Magnetic Sphincter Augmentation Device for Gastroesophageal Reflux

Robert A. Ganz,^{*} Steven A. Edmundowicz,[‡] Paul A. Taiganides,[§] John C. Lipham,^{||} C. Daniel Smith,^{||} Kenneth R. DeVault,[#] Santiago Horgan,^{**} Garth Jacobsen,^{**} James D. Luketich,^{‡‡} Christopher C. Smith,^{§§} Steven C. Schlack-Haerer,^{|||} Shanu N. Kothari,^{|||} Christy M. Dunst,^{##} Thomas J. Watson,^{***} Jeffrey Peters,^{‡‡‡} Brant K. Oelschlager,^{§§§} Kyle A. Perry,^{||||} Scott Melvin,^{||||} Willem A. Bemelman,^{|||} André J. P. M. Smout,^{###} and Dan Dunn^{****}

Minnesota Gastroenterology PA, Plymouth, Minnesota; ‡Division of Gastroenterology, Washington University School of Medicine, St. Louis, Missouri; §Knox Regional Heartburn Treatment Center, Mount Vernon, Ohio; ||Department of Surgery, Keck School of Medicine, University of Southern California, Los Angeles, California; ||Department of Surgery, #Department of Gastroenterology and Hepatology, Mayo Clinic, Jacksonville, Florida; **Department of Surgery, University of California at San Diego, San Diego, California; ‡‡Division of Thoracic Surgery, University of Pittsburgh, Pittsburgh, Pennsylvania; §§Southern Reflux Center at Albany Surgical Center, Albany, Georgia; |||Department of Gastroenterology, |||Department of Surgery, Gundersen Health System, LaCrosse, Wisconsin; ##Gastrointestinal and Minimally Invasive Surgery Division, The Oregon Clinic, Portland, Oregon; *Department of Surgery, University of Rochester School of Medicine and Dentistry, Rochester, New York; ‡‡‡University Hospitals, Cleveland, Ohio; §§§Department of Surgery, University of Washington, Seattle, Washington; ||||Department of Surgery, The Ohio State University, Columbus, Ohio; |||Department of Surgery, ###Division of Gastroenterology, Academic Medical Center, University of Amsterdam, Amsterdam, The Netherlands; ****Division of Surgery, Abbott-Northwestern Hospital, Minneapolis, Minnesota*

BACKGROUND & AIMS:

Based on results from year 2 of a 5-year trial, in 2012 the US Food and Drug Administration approved the use of a magnetic device to augment lower esophageal sphincter function in patients with gastroesophageal reflux disease (GERD). We report the final results of 5 years of follow-up evaluation of patients who received this device.

METHODS:

We performed a prospective study of the safety and efficacy of a magnetic device in 100 adults with GERD for 6 months or more, who were partially responsive to daily proton pump inhibitors (PPIs) and had evidence of pathologic esophageal acid exposure, at 14 centers in the United States and The Netherlands. The magnetic device was placed using standard laparoscopic tools and techniques. Eighty-five subjects were followed up for 5 years to evaluate quality of life, reflux control, use of PPIs, and side effects. The GERD-health-related quality of life (GERD-HRQL) questionnaire was administered at baseline to patients on and off PPIs, and after placement of the device; patients served as their own controls. A partial response to PPIs was defined as a GERD-HRQL score of 10 or less on PPIs and a score of 15 or higher off PPIs, or a 6-point or more improvement when scores on vs off PPI were compared.

RESULTS:

Over the follow-up period, no device erosions, migrations, or malfunctions occurred. At baseline, the median GERD-HRQL scores were 27 in patients not taking PPIs and 11 in patients on PPIs; 5 years after device placement this score decreased to 4. All patients used PPIs at baseline; this value decreased to 15.3% at 5 years. Moderate or severe regurgitation occurred in 57% of subjects at baseline, but only 1.2% at 5 years. All patients reported the ability to belch and vomit if needed. Bothersome dysphagia was present in 5% at baseline and in 6% at 5 years. Bothersome gas-bloat was present in 52% at baseline and decreased to 8.3% at 5 years.

CONCLUSIONS:

Augmentation of the lower esophageal sphincter with a magnetic device provides significant and sustained control of reflux, with minimal side effects or complications. No new safety risks

emerged over a 5-year follow-up period. These findings validate the long-term safety and efficacy of the magnetic sphincter augmentation device for patients with GERD. [ClinicalTrials.gov](https://clinicaltrials.gov/ct2/show/study/NCT00776997) no: NCT00776997.

Keywords: Heartburn; Hiatal Hernia; Clinical Trial; Surgery.

Gastroesophageal reflux disease (GERD) is a serious condition because of the potential for chronic symptoms and complications, and its association with Barrett's esophagus and esophageal adenocarcinoma.¹ Fundamental to the disease process is an incompetent lower esophageal sphincter (LES) that allows abnormal reflux of gastric content into the esophagus. The gastric refluxate, which contains varying concentrations of acid, pepsin, enzymes, and other content, influences symptoms and mucosal damage by its type, acidity, volume, and exposure time via contact with esophageal surfaces.^{2,3} Acid-suppression therapy, in the form of proton pump inhibitors (PPIs), is the primary treatment for GERD. This drug class has been shown to be most effective for acid-related symptoms, such as heartburn and esophagitis, and less effective for regurgitation because PPI therapy does not address the underlying incompetency of the LES.⁴ Acid-suppression therapy may change the composition of the refluxate, particularly its acidity, but it does not prevent abnormal reflux, leaving patients at risk for ongoing symptoms and progression of disease.⁵

Esophagogastric fundoplication addresses the incompetent LES by mobilizing the gastric fundus to form a fundic wrap around the distal esophagus, resulting in permanent loss of normal gastric fundic anatomy, and involves dissection of the phreno-esophageal ligaments, which secure the esophagus to the diaphragm.⁶ Nissen fundoplication has long been associated with effective reflux control, albeit at the expense of inducing new side effects, such as gas-bloat, flatulence, and inability to vomit.^{7,8} The placement of a magnetic sphincter augmentation device (LINX Reflux Management System; Torax Medical, Inc, Shoreview, MN) is the only antireflux procedure that mechanically restores competency to the reflux barrier without using the gastric fundus.^{9,10} Based on 2-year results, the Food and Drug Administration (FDA) granted approval of the magnetic device for GERD in 2012.^{11,12} The final results of the 5-year magnetic sphincter augmentation study are reported.

Methods

Study Design

This was a prospective, multicenter, single-arm study with predefined success criteria. Each patient served as his or her own control, with the treatment effect assessed by comparing follow-up assessments with baseline. This study purposely was designed to provide valid scientific

evidence to support FDA approval. Both objective and subjective evaluations were performed to evaluate the treatment effect. The authors had access to the study data at all times and the co-authors reviewed and approved all manuscript drafts and the final manuscript.

Patients

A total of 14 centers (13 in the United States and 1 in The Netherlands) enrolled patients. Eligible patients were 18 to 75 years old, had at least a 6-month history of GERD, a partial response to daily PPIs, and pathologic esophageal acid exposure confirmed by pH monitoring. Exclusion criteria included evidence of hiatal hernia greater than 3 cm, esophagitis grade C or D according to the Los Angeles classification, body mass index higher than 35, Barrett's esophagus, or motility disorder. In the study, the Gastroesophageal Reflux Disease-Health Related Quality of Life (GERD-HRQL) questionnaire was administered both with and without PPIs before treatment to assess changes in the total score. Per the protocol, a subject was considered a partial PPI responder if the following inclusion criterion were met: subjects with persistent reflux symptoms and partial symptomatic improvement on PPI therapy shown by a GERD-HRQL score of 10 or less on PPI and 15 or higher off PPI, or subjects with a 6-point or more improvement when comparing their GERD-HRQL score on PPI and off PPI.

Study Procedures

The baseline screening, surgical technique, and follow-up evaluation were reported previously.¹² The magnetic device was placed by foregut surgeons using standard laparoscopic tools and techniques. A crural repair was performed at the surgeon's discretion; cruroplasty was performed in 34% of patients. The device uses magnetic attraction to create resistance to an abnormal opening of the LES to prevent reflux events, but still allows normal LES opening for swallowing food, belching, and vomiting (Figure 1).

Postapproval Evaluations

The efficacy end points after FDA approval were the same as before approval, with the exception that esophageal pH monitoring was performed after the procedure only at 1 year and these results were reported previously.¹² Quality of life was measured with the GERD-HRQL questionnaire.¹³ Total scores range from

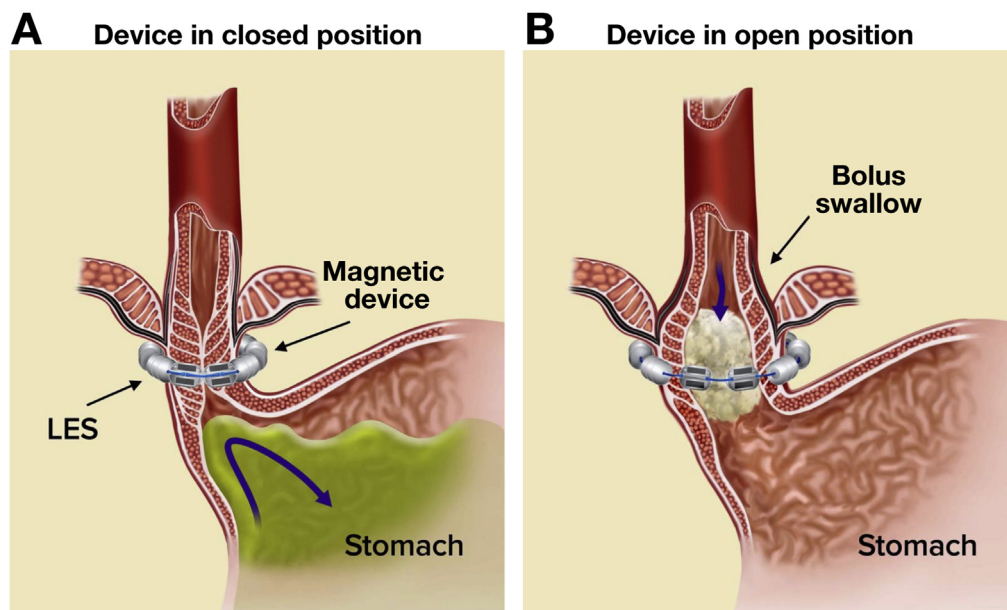


Figure 1. Magnetic sphincter augmentation. (A) In the closed position, the magnetic attraction of the beads augments the lower esophageal sphincter to prevent its opening and subsequent reflux of gastric content into the esophagus. (B) The device is shown in the open position, which allows for normal physiologic function such as transport of food, belching, and vomiting.

0 to 50, with higher scores indicating worse symptoms. For those patients who had resumed PPIs, the dose and frequency were recorded, and the PPI was stopped for at least 7 days before completing the questionnaires. Postapproval efficacy end points included the following: the number of patients achieving at least a 50% reduction in the GERD-HRQL score as compared with the baseline score without PPIs; and a reduction of at least 50% in the dose of PPIs compared with baseline. The efficacy end point was achieved if met by at least 60% of patients.

Additional side effects and reflux-related symptoms were actively queried before and after treatment with the Foregut Symptoms Questionnaire.¹⁴ The 5-year evaluation included endoscopy to evaluate the presence of esophagitis, Barrett's esophagus, or device erosion. Chest radiography was used to confirm the device remained at the gastroesophageal junction.

Statistical Analysis

Postapproval analyses were performed on GERD-HRQL scores and use of PPIs per the predefined success criteria. Safety was monitored throughout the postapproval period as the rate and type of serious adverse events related to the device or implant procedure.

Continuous variables were summarized with the use of standard descriptive statistics (eg, mean, standard deviation, median, range). Categorical variables were summarized via frequency distributions. The 2-tailed, paired Student *t* test or the Wilcoxon signed rank test were used to compare before and after implant values for continuous outcomes and the McNemar test was used to assess changes in binary outcomes from before to after implant. Differences were considered significant at a *P* value of less than .05.

Results

Patient Characteristics

The study population consisted of 100 patients, 52% males and 48% females. The median age at the time of implant was 53 years (range, 18–75 y), with a median body mass index of 28 (range, 20–35). The median duration of reflux symptoms was 10 years (range, 1–40 y). The median duration of treatment with PPIs was 5 years (range, <1 to 20 y). Each patient had confirmed pathologic esophageal acid exposure without PPIs (median percentage of time pH was less than 4 was 10.9%; range, 4.8%–25.4%). Eighty-five patients had a follow-up evaluation at 5 years; a few analyses were performed on 84 patients if data were incomplete, and 82 patients completed endoscopy at the 5-year mark. A consolidated standards for the reporting of trials diagram is provided in the [Supplementary Appendix](#).

Efficacy Success Criteria at 5 Years

A 50% or greater reduction in GERD-HRQL score was achieved in 83% of patients at 5 years (70 of 84; 95% confidence interval, 73–91) (Figure 2). A reduction of 50% or more in the average daily dose of PPIs occurred in 89.4% of patients at 5 years (76 of 85 patients; 95% confidence interval, 81–95) (Figure 2). Per the predefined criteria, long-term efficacy was maintained.

Additional Reflux Analyses

Additional analyses, using the GERD-HRQL and Foregut Symptoms Questionnaire, were performed (84 patients were available for these analyses). Patients with moderate or severe heartburn had a decrease from 89%

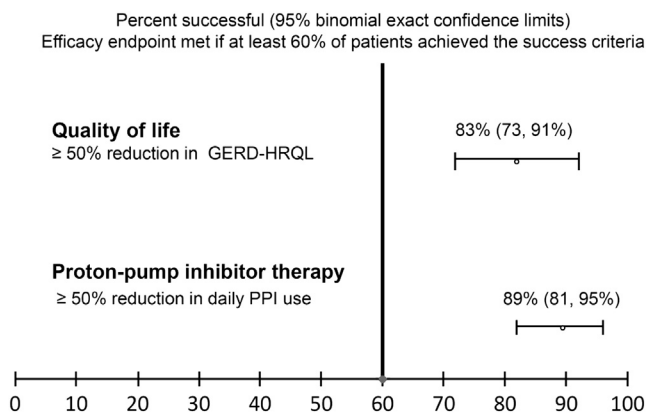


Figure 2. Summary of efficacy endpoints at 5 years. At 5 years, the endpoints of quality of life and reduction in PPI use was met if at least 60% of patients achieved the success criteria. For quality of life, 83% achieved at least a 50% reduction in total GERD-HRQL score, with a lower-bound confidence interval of 73%. For reduction in proton pump inhibitor use, 89% achieved at least a 50% reduction in daily proton pump inhibitor use, with a lower-bound confidence interval of 81%.

to 11.9%, and moderate or severe regurgitation decreased from 57% to 1.2% without use of PPIs at baseline and 5 years. Patient dissatisfaction before treatment was 95%, and decreased to 7.1% at 5 years (Figure 3) ($P < .001$ for all comparisons with baseline).

Daily use of PPIs was 100% at baseline and decreased to 15.3% at 5 years. At 5 years, 75.3% of patients reported complete cessation of PPIs, and 9.4% reported PPI use only as needed. Thus, 84.7% were either completely off PPIs or reported use as needed at 5 years after surgery. Patients who required double-dose PPIs decreased from 36% at baseline to 2.4% at 5 years. Of the patients reporting dissatisfaction at 5 years, all but 1 (5 of 6) reported daily use of PPIs (Figure 4).

Comparing the total GERD-HRQL scores at 5 years without PPIs with scores with and without PPIs at baseline, the median total score at baseline was 27 without PPIs and 11 with PPIs, and the score decreased to 4 after surgery at 5 years ($P < .001$ for all comparisons with baseline) (Figure 5). The median GERD-HRQL score for patients reporting any use of PPIs within 30 days of the 5-year follow-up period was 7 (after PPIs were discontinued for at least 1 week) and 2.5 for patients reporting no PPIs.

Esophagitis

Healing of esophagitis occurred in 76.5% (26 of 34) of patients evaluated at 5 years. Among the 8 patients with ongoing esophagitis, 6 patients had grade A and the other patients had grade B. Of the patients without esophagitis at baseline and evaluated at 5 years, 90% (43 of 48) continued to have no esophagitis. Among the 5 patients with de novo esophagitis, 4 patients had grade A and 1 patient had grade B. No patients developed Barrett's esophagus during the study.

Other Symptoms

Other symptoms commonly associated with antireflux surgery or reflux disease were minimal at 5 years compared with baseline (Figure 6). All patients reported the ability to belch and vomit (if needed). Patients reporting bothersome swallowing was 5% at baseline and 6% at 5 years ($P = .739$); symptoms of bloating/gas decreased from 52% at baseline to 8.3% at 5 years ($P < .001$). In addition, per the Foregut Symptom Questionnaire, patients reported less diarrhea ($P = .103$),

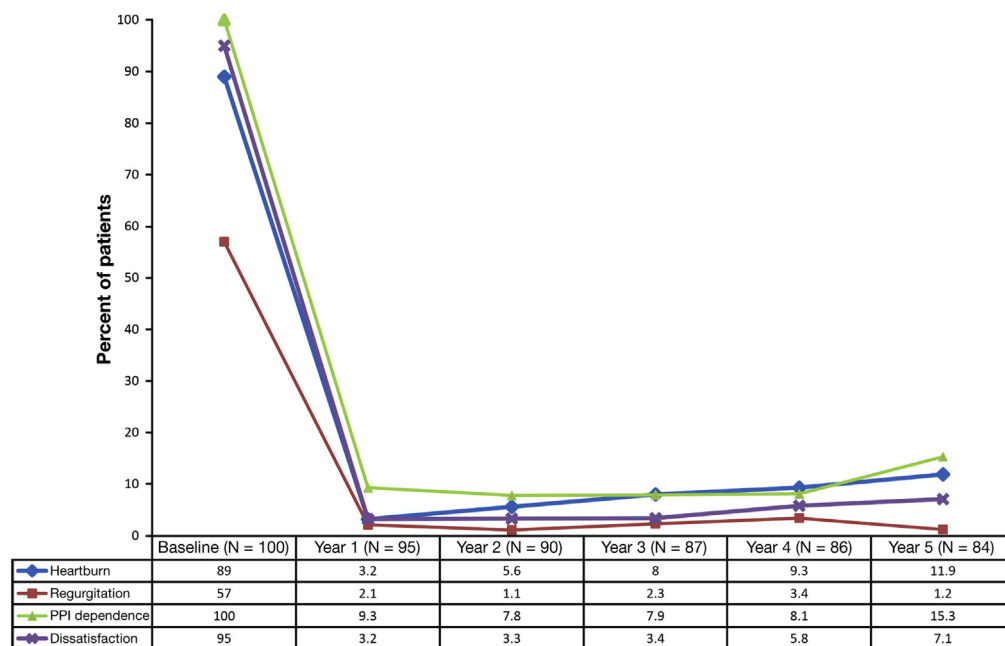


Figure 3. Reflux control before and after magnetic sphincter augmentation. Change in baseline compared with 1 to 5 years after magnetic sphincter augmentation for moderate-severe heartburn, moderate-severe regurgitation, proton-pump inhibitor dependence, and dissatisfaction ($P < .001$ between baseline and follow-up evaluation for all comparisons).

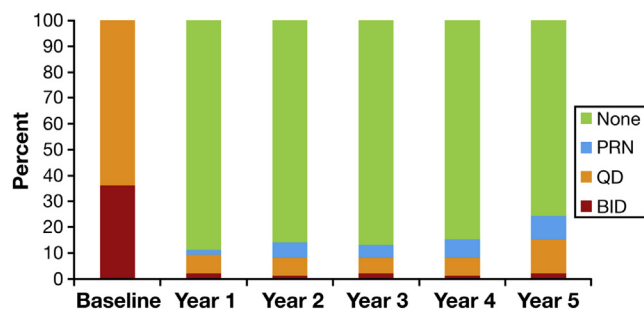


Figure 4. Use of PPIs at baseline through year 5. PPI use was categorized as none, as needed (PRN), once a day (QD), and twice a day (BID) at each visit, based on the prior 30 days.

constipation ($P = .008$), and nausea/vomiting ($P = .003$) after treatment.

Safety

Since the last report at 3 years, no new safety concerns have emerged.¹² No device erosions, migrations, or malfunctions occurred in this study. Device removal occurred in 7 patients. In 4 of the patients, the device was removed at 21, 31, 93, and 1807 days after implantation because of persistent dysphagia, with resolution after removal. One patient had the device removed at 357 days owing to intermittent vomiting of unknown cause starting 3 months after placement, without relief after removal. The device was removed in 1 patient at 489 days because of persistent reflux symptoms and another device was removed at 1062 days because of persistent chest pain. Three patients subsequently underwent uneventful Nissen fundoplication after device removal.

Discussion

Persistent symptoms of heartburn and regurgitation warrant careful monitoring. Ignoring persistent reflux

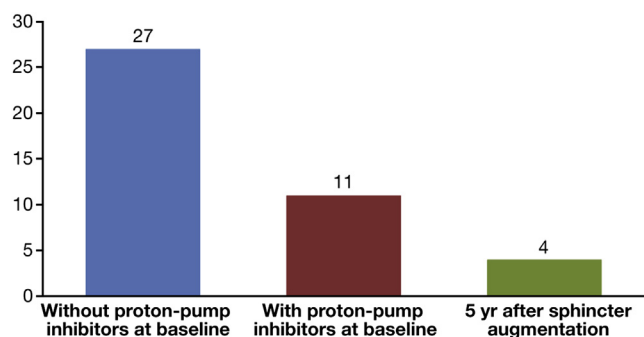


Figure 5. Median total GERD-HRQL score. Median score from the GERD-HRQL measures at baseline without and with proton pump inhibitors, as compared with magnetic sphincter augmentation at 5 years. Higher scores indicate worse symptoms. There was significant improvement in the median score at 5 years, as compared with baseline, both without and with proton pump inhibitor use.

symptoms can lead to severe complications, such as esophageal strictures, Barrett's esophagus, and esophageal adenocarcinoma.¹⁵ Consideration of other treatments may become necessary when medical therapy fails to control symptoms. In the current study, we enrolled patients who had been treated with PPIs for several years, who still did not obtain adequate reflux control. These patients sought surgical treatment, but elected to forego conventional fundoplication surgery, instead opting for esophageal sphincter augmentation using a magnetic device.

The majority of patients reported moderate or severe regurgitation at baseline in this study, symptoms for which PPIs largely are ineffective.^{16,17} Five years after magnetic sphincter device placement, moderate or severe regurgitation was eliminated in all but 1 of 57 patients. Without a procedure to correct an incompetent LES, it is unlikely that continued medical therapy would have improved these reflux symptoms, and the severity and frequency of the symptoms may have worsened.¹⁸

In this study, side effects commonly associated with Nissen fundoplication largely were absent, consistent with other studies of the magnetic device.^{12,19-21} Louie et al²² provided a rationale for the difference in side-effect profile between the magnetic device and Nissen fundoplication: Nissen fundoplication reduces the total number of reflux episodes to less than what is considered normal, creating a "super-normal" sphincter that is highly effective at preventing reflux but to the point of preventing or decreasing venting of ingested air under normal circumstances. The inability to vent (ie, belch) and the reduced number of normal reflux episodes after Nissen fundoplication likely is associated with the side effects of bloating and flatulence. In contrast, the magnetic device results in more normal sphincter function.²²

The rate of laparoscopic device removal was 7% over a 5-year period and has been reported to be 3% in another study spanning 6 years of clinical experience.²¹ These rates are less than the expected range for reoperation after laparoscopic fundoplication at 5 years.²³⁻²⁶ Reoperation rates for transoral fundoplication at 5 years are not available, but revision rates from shorter-term experiences have been reported to be between 11.5% and 52.6%.²⁷⁻³⁰ Importantly, all device removals in our study were performed electively with no procedure-related complications, whereas reoperations after laparoscopic fundoplication often are associated with a higher rate of complications and morbidity.^{31,32} It appears that the severity of complications and risks associated with reoperation are less after magnetic sphincter augmentation than fundoplication.³³⁻³⁵

Importantly, in this long-term study, no device erosions occurred. Other investigators³⁶ have reported an erosion rate of much less than 1%. The magnetic sphincter augmentation device was engineered specifically to minimize the risk of device erosion and overcome the problems of previous barrier devices.³⁷ The device provides sphincter augmentation by means of

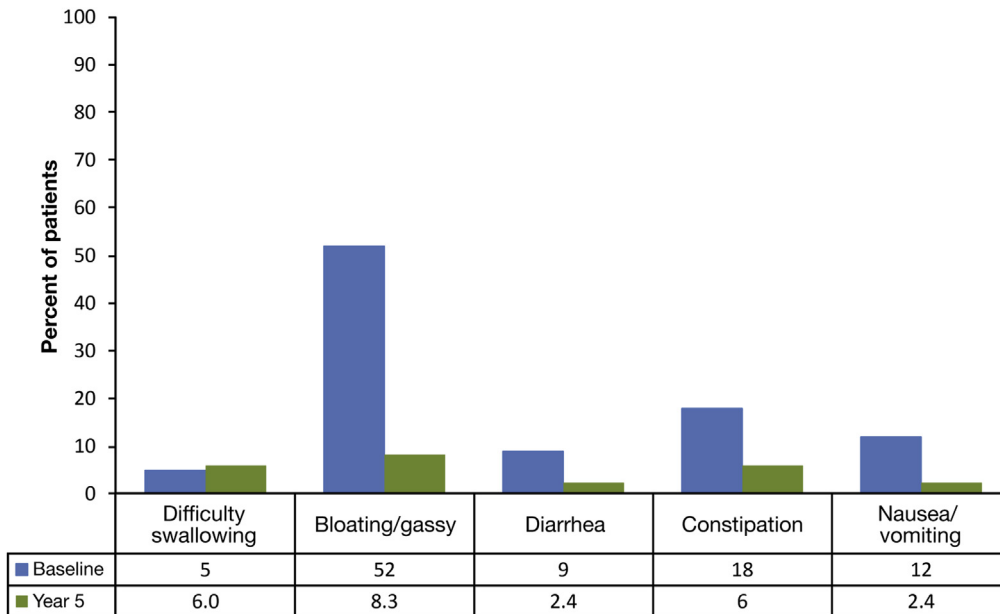


Figure 6. Other symptoms after magnetic sphincter augmentation. Comparison at baseline and 5 years after magnetic sphincter augmentation for other symptoms experienced by reflux patients, such as difficulty swallowing ($P = .739$), bloating/gassy feeling ($P < .001$), diarrhea ($P = .103$), constipation ($P = .008$), and nausea/vomiting ($P = .003$).

dynamic, expansible magnetic forces, not bulk or compression. The device mirrors physiologic LES opening and closing in that it opens for food bolus transport (its opening area can increase more than the esophagus), and shows progressively less force the larger the bolus, as opposed to alternative rigid designs that use fixed diameters around the esophagus, allowing for little or no device distention. Long-term clinical experience confirms that the magnetic sphincter augmentation device design is not prone to cause esophageal wall erosions.

This study had some limitations. Per the FDA-approved protocol, esophageal pH testing and manometry were not performed beyond 1 year. Manometry data have been reported previously with no significant change in any manometric parameter.¹² Esophageal pH results at 1 year showed that the majority of the patients had normalization of esophageal acid exposure along with symptomatic improvement and discontinuation of PPIs.¹² Longer-term pH data would have strengthened our conclusions. In addition, the study did not have a comparison group. Instead the trial design allowed for assessment of long-term outcomes via rigorous follow-up compliance, which is important in a chronic disease state such as GERD. This study describes a long and complete multicenter follow-up evaluation of a novel GERD-device cohort, used predefined success criteria, and purposely was designed to provide valid scientific evidence to support FDA approval. Both objective (pH and manometry) and subjective evaluations were performed to evaluate the treatment effect. Consistent with clinical practice, the extended 5-year follow-up period focused on both maintenance and durability of symptom improvement, and discontinuation of PPI therapy, and the objective clinical evidence of reduction in esophageal acid exposure was corroborated by the subjective findings. The consistent results of this 5-year study provide confidence that when used as indicated, there is a high

probability that magnetic sphincter augmentation will improve the antireflux barrier and provide durable clinical benefits.

In conclusion, this study showed that patients with chronic GERD and failed long-term PPI therapy benefited from surgical intervention with magnetic sphincter augmentation. Long-term safety and efficacy have been validated for this procedure. It should be considered a first-line therapy for patients and physicians seeking a fundic-sparing antireflux procedure.

Supplementary Material

Note: To access the supplementary material accompanying this article, visit the online version of *Clinical Gastroenterology and Hepatology* at www.cghjournal.org, and at <http://dx.doi.org/10.1016/j.cgh.2015.05.028>.

References

1. Lagergren J, Reinhold B, Lindgren A, et al. Symptomatic gastroesophageal reflux as a risk factor for esophageal adenocarcinoma. *N Engl J Med* 1999;340:825–831.
2. Woodland P, Sifrim D. The refluxate: the impact of its magnitude, composition and distribution. *Best Pract Res Clin Gastroenterol* 2010;24:861–871.
3. Pearson JP, Parikh S, Orlando RC, et al. Review article: reflux and its consequences – the laryngeal, pulmonary and oesophageal manifestations. Conference held in conjunction with the 9th International Symposium on Human Pepsin (ISHP) Kingston-upon-Hull, UK, 21–23 April 2010. *Aliment Pharmacol Ther* 2011; 33:1–71.
4. Kahrilas P, Jonsson A, Denison H, et al. Regurgitation is less responsive to acid suppression than heartburn in patients with gastroesophageal reflux disease. *Clin Gastroenterol Hepatol* 2012;10:612–619.
5. Blonski W, Vela MF, Castell DO. Comparison of reflux frequency during prolonged multichannel intraluminal impedance and pH

- monitoring on and off acid suppression therapy. *J Clin Gastroenterol* 2009;43:816–820.
6. Spivak H, Lelcuk S, Hunter JG. Laparoscopic surgery of the gastroesophageal junction. *World J Surg* 1999;23:356–367.
 7. Humphries L, Hernandez J, Clark W, et al. Causes of dissatisfaction after laparoscopic fundoplication: the impact of new symptoms, recurrent symptoms, and the patient experience. *Surg Endosc* 2013;27:1537–1545.
 8. Kessing BF, Broeders JA, Vinke N, et al. Gas-related symptoms after antireflux surgery. *Surg Endosc* 2013;27:3739–3747.
 9. Woodland P, Amarasinghe G, Sifrim D. Emerging therapeutic options in GERD. *Best Pract Res Clin Gastroenterol* 2013;27:455–467.
 10. Bonavina L, DeMeester TR, Ganz RA. LINX™ Reflux Management System: magnetic sphincter augmentation in the treatment of gastroesophageal reflux disease. *Expert Rev Gastroenterol Hepatol* 2012;6:667–674.
 11. Summary of safety and effectiveness data: LINX Reflux Management System. Available at: http://www.accessdata.fda.gov/crdh_docs/pdf10/P100049b.pdf. Accessed: January 21, 2015.
 12. Ganz RA, Peters JH, Horgan S, et al. Esophageal sphincter device for gastroesophageal reflux disease. *N Engl J Med* 2013;368:719–727.
 13. Velanovich V. Comparison of generic (SF-36) vs. disease-specific (GERD-HRQL) quality of life scales for GERD. *J Gastrointest Surg* 1998;2:141–145.
 14. DeMeester TR, Bonavina L, Albertucci M. Nissen fundoplication for gastroesophageal reflux disease. *Ann Surg* 1986;204:9–20.
 15. Fennerty MB. The continuum of GERD complications. *Cleve Clin J Med* 2003;70(Suppl 5):S33.
 16. Kahrilas PJ, Jonsson A, Denison H, et al. Impact of regurgitation on health-related quality of life in gastroesophageal reflux disease before and after short-term potent acid suppression therapy. *Gut* 2014;63:720–726.
 17. Clayton SB, Rife CC, Singh ER, et al. Twice-daily proton pump inhibitor therapy does not decrease the frequency of reflux episodes during nocturnal recumbency in patients with refractory GERD. *Dis Esophagus* 2012;25:682–686.
 18. Malfertheiner P, Nocon M, Vieth M, et al. Evolution of gastroesophageal reflux disease over 5 years under routine medical care – the ProGERD study. *Aliment Pharmacol Ther* 2012;35:154–164.
 19. Riegler M, Schoppman SF, Bonavina L, et al. Magnetic sphincter augmentation and fundoplication for GERD in clinical practice: one-year results of a multicenter, prospective observational study. *Surg Endosc* 2015;29:1123–1129.
 20. Lipham JC, DeMeester TR, Ganz RA, et al. The LINX® reflux management system: confirmed safety and efficacy now at 4 years. *Surg Endosc* 2012;26:2944–2999.
 21. Bonavina L, Saino G, Bona D, et al. One hundred consecutive patients treated with magnetic sphincter augmentation for gastroesophageal reflux disease: 6 years of clinical experience from a single center. *J Am Coll Surg* 2013;217:577–585.
 22. Louie BE, Farivar AS, Schultz D, et al. Short-term outcomes using magnetic sphincter augmentation versus nissen fundoplication for medically resistant gastroesophageal reflux disease. *Ann Thorac Surg* 2014;98:498–505.
 23. Broeders JA, Roks DJ, Ali UA, et al. Laparoscopic anterior 180-degree versus Nissen fundoplication for gastroesophageal reflux disease: systematic review and meta-analysis of randomized clinical trials. *Ann Surg* 2013;257:850–859.
 24. Baigrie RJ, Cullis SN, Ndhuni AJ, et al. Randomized double-blind trial of laparoscopic Nissen fundoplication versus anterior partial fundoplication. *Br J Surg* 2005;92:819–823.
 25. Cao W, Watson DI, Lally CJ, et al. Ten-year clinical outcome of a prospective randomized clinical trial of laparoscopic Nissen versus anterior 180 (degrees) partial fundoplication. *Br J Surg* 2008;95:1501–1505.
 26. Watson DI, Jamieson GC, Pike GK, et al. Five-year follow-up of a randomized clinical trial of laparoscopic total versus partial anterior 180 degrees fundoplication. *Br J Surg* 1999;86:123–130.
 27. Hoppo T, Immanuel A, Schuchert M, et al. Transoral incisionless fundoplication 2.0 procedure using EsophyX™ for gastroesophageal reflux disease. *J Gastrointest Surg* 2010;14:1895–1901.
 28. Witterman B, Strijkers R, de Vries E, et al. Transoral incisionless fundoplication for treatment of gastroesophageal reflux disease in clinical practice. *Surg Endosc* 2012;26:3307–3315.
 29. Muls V, Eckhardt AJ, Marchese M, et al. Three-year results of a multicenter prospective study of transoral incisional fundoplication. *Surg Innov* 2013;20:321–330.
 30. Demyttenaere SV, Bergman S, Pham T, et al. Transoral incisionless fundoplication for gastroesophageal reflux disease in an unselected patient population. *Surg Endosc* 2010;24:854–858.
 31. Furnee JB, Draaisma WA, Broeders IAMJ, et al. Surgical re-intervention after failed antireflux surgery: a systematic review of the literature. *J Gastrointest Surg* 2009;13:1539–1549.
 32. Symons NR, Purkayastha S, Dillemans B, et al. Laparoscopic revision of failed antireflux surgery: a systematic review. *Am J Surg* 2011;202:336–343.
 33. Richter JE. Gastroesophageal reflux disease treatment: side effects and complications of fundoplication. *Clin Gastroenterol Hepatol* 2013;11:465–471.
 34. Titus JM, Mason DP, Raymond DP, et al. Esophagopulmonary fistula and left lung abscess after transoral incisionless fundoplication. *Ann Thorac Surg* 2013;96:689–691.
 35. Hawa E, El-Bakush A, Nugent K. Esophageal perforation and bilateral empyema following endoscopic EsophyX transoral incisionless fundoplication. *Clin Endosc* 2014;47:560–563.
 36. Lipham JC, Taiganides PA, Louie BE, et al. Safety analysis of first 1000 patients treated with magnetic sphincter augmentation for gastroesophageal reflux disease. *Dis Esophagus* 2015;28:305–311.
 37. Ganz RA, Gostout CJ, Grudem J, et al. Use of a magnetic sphincter for the treatment of GERD: a feasibility study. *Gastrointest Endosc* 2008;67:287–294.

Reprint requests

Address requests for reprints to: Robert A. Ganz, MD, FASGE, Minnesota Gastroenterology PA, 15700 37th Avenue North, Suite 300, Plymouth, Minnesota 55446. e-mail: rganz@mngastro.com; fax: (612) 870-5837.

Conflicts of interest

These authors disclose the following: Paul Taiganides, John Lipham, C. Daniel Smith, Santiago Horgan, and Shanu N. Kothari have served as consultants to Torax Medical and have received honoraria.

Funding

The study was funded by Torax Medical, Inc. This study was designed cooperatively by the sponsor (Torax Medical, Inc, Shoreview, MN), the study investigators, and the Food and Drug Administration.